

AGGRESSIVE FIBROMATOSIS OF MANDIBLE: A CASE REPORT AND LITERATURE REVIEW

NIMISHA SINGH^{1,*}, VIBHA SINGH¹, SATISH DHASMANA², RIDHI JAISWAL³, GAGAN MEHTA¹

¹Department of Oral and Maxillofacial Surgery, K.G. Medical University, Lucknow, Uttar Pradesh, India, ²Department of Anaesthesia, R.M.L. Institute of Medical Sciences, Lucknow, Uttar Pradesh, India, ³Department of Pathology and Microbiology, K.G. Medical University, Lucknow, Uttar Pradesh, India

*Address for Correspondence: Dr. Vibha Singh, Professor, Dept.s of Oral and Maxillofacial Surgery, K.G. Medical University, Lucknow, Uttar Pradesh, India,
email: vibhasinghraghuvanshi@gmail.com

ABSTRACT

Aggressive fibromatosis or desmoid tumor is a benign but locally-aggressive tumor, which most often affects the muscles of the shoulder, the pelvic girdle, and the thigh. This tumor has high potential for loco regional extension. It is very rarely located in the mandible. The differential diagnosis with malignant tumors is difficult. Surgery is the first-line treatment. However, alternative therapies should be considered, especially in children, to avoid mutilating operations. This article reports a case of aggressive fibromatosis involving mandible in a 13 year old female and literature review.

Keywords: Desmoid, Fibromatosis, Mandible.

INTRODUCTION

Desmoid tumors (DT), also called aggressive fibromatosis (AF), are rare neoplasms, occurring both sporadically and in the context of familial adenomatous polyposis, also recognized as Gardner's syndrome. Fibromatoses are a group of fibrous connective tissue lesions that are morphologically classified as benign neoplasms. They do not usually develop distant metastasis, however, locally they show an aggressive and infiltrative behavior. The low incidence of this rare tumor presents problems in both diagnosis and management. Juvenile aggressive fibromatosis affects infants and children and requires radical surgery.

Stout^[1] first described 'juvenile fibromatosis' as a non-congenital disease affecting children younger than 16 years. There are two types of juvenile aggressive fibromatosis, superficial and deep. The superficial variant is not aggressive, does not grow faster, and does not invade deep tissues. By contrast, deep fibromatosis is more aggressive and invades other tissues. Some authors tend to classify it as a fibroblastic proliferative disorder different from neoplasia^[2].

This variant affects young children, especially those from 18 months to 3 years old, and females in a 3:1 ratio over males^[3]. It affects different regions of the body but especially the neck and face, specifically the tongue and lower jaw^[2,3,4,5]. This disease is characterized by a massive infiltration of muscle, fat tissue, and bone.

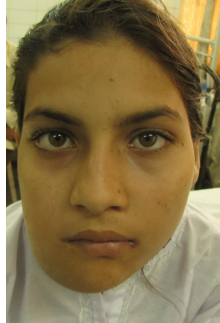The etiology is unknown. Multiple factors are thought to influence pathogenesis including genetic, trauma and endocrine factors. Membrane-specific estrogen and progesterone receptors have been implicated in desmoids in pregnancy and steroid hormones play a vital role in the dysregulation of fibroblast activity. Loss of the Y chromosome and deletion of 5q chromosome may occur^[6].

Fibromatosis occurs mostly in the lower abdominal wall of females during or after pregnancy^[7]. Extra abdominal fibromatosis often affects the muscles of the shoulder and pelvic girdles. Between 7% and 15% of AFs occur in the head and neck region, 26% of which arise from the soft tissues (including the periosteum) around the mandible^[8,9]. Fibromatoses are more common in females than males at a ratio of 3:2

or even higher for the abdominal desmoids [9].

Although fibromatosis can affect any age group from neonatal to elderly, it is predominantly a disease of children and young adults. Twenty five percent of all AFs occur in children under 15 years of age^[1]. Surgical ablation in this kind of tumor should be radical, as there is a high rate of recurrences after more conservative treatment [5,10,11].

CASE REPORT



A 13 year old female presented to Outpatient Department of Oral & Maxillofacial Surgery, K.G.Medical University, Lucknow with a firm swelling

Fig 1: Frontal view showing large swelling of right lateral mandible.

in the right lateral mandible measuring 11x6 cm, without involvement of skin or gingiva. (Fig. 1)

There was no history of trauma to the face or neck and no complaints of pain, voice change, or dysphagia. No relevant diseases were reported in the family. A general physical examination was normal. Oral and maxillofacial examination revealed a large swelling of the right lateral mandible. It extended from the right ramus of the mandible to the left parasymphiseal region, crossing the mid line. The mass was firm, hard, non-pulsating, and measured 11x6 cm. The swelling obliterated the right buccal sulcus and was palpable in the floor of the mouth. The overlying skin and mucosa were normal. No cervical lymphadenopathy was present.

The orthopantomograph revealed a radio-lucent lesion with ill-defined borders extending from the right mandibular ramus to the left parasymphysis (Fig. 2). A CT scan showed a tumour arising from the right mandibular ramus, extending to the anterior mandibular body, crossing midline with erosion of the lingual and buccal cortical plates at some places, and extending towards the floor of the mouth and submandibular area (Fig. 3).

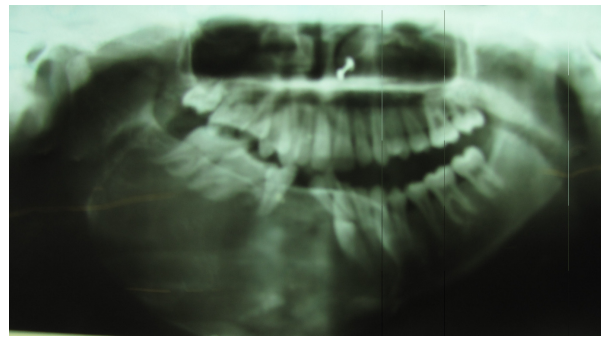


Fig 2: OPG showing radio-lucent lesion from the right mandibular ramus to left parasymphysis.

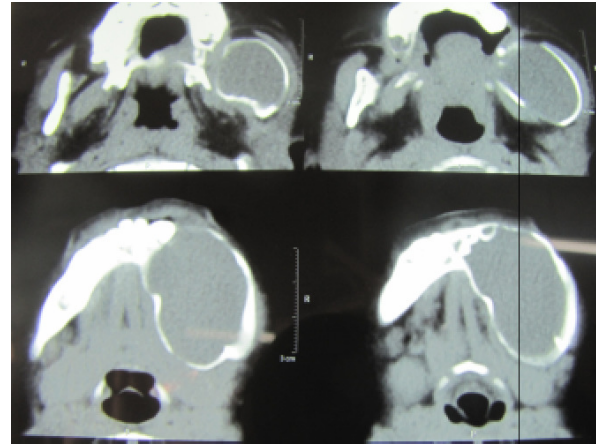


Fig 3: CT scan showing radiolucent tumor.

The patient underwent an intraoral incisional biopsy. Sections show a benign mesenchymal tumor disposed in bundles or fascicles or an interlacing pattern. The fascicles comprise of oval to elongated cells having uniform spindle nuclei (Fig. 4a). Collagen formation is seen. At the periphery several bone trabeculae rimmed by osteoblasts and covered by squamous epithelium are seen (Fig. 4b). The histological examination revealed aggressive fibromatosis.

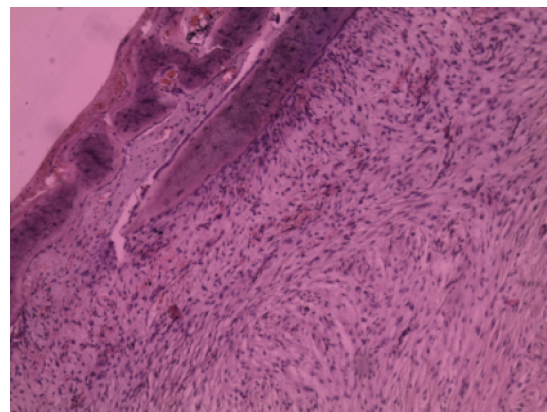


Fig 4a: Microscopic picture showing mesenchymal tumor disposed in intersecting fascicles.

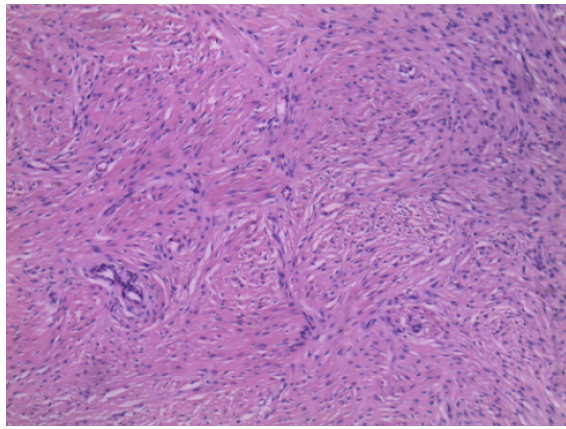


Fig 4b: Microscopic picture showing osteoid rimming the tumor tissue.

The patient was planned for surgery under general anaesthesia for radical excision. A right mandibulectomy was performed via a submandibular incision (Fig 5, 6). Immediate reconstruction was performed by using reconstruction plate (Fig. 7).

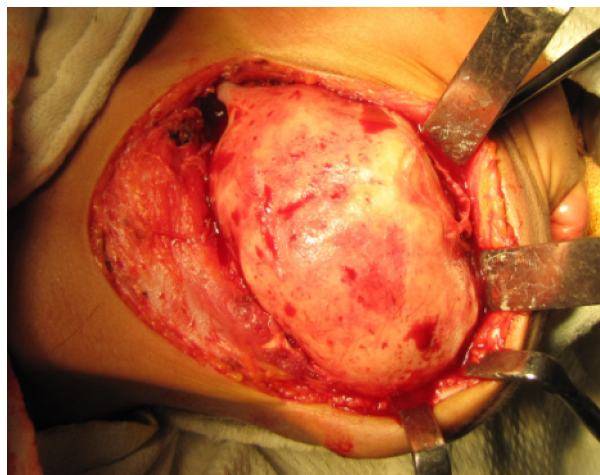

Fig 5: Exposure of tumor via submandibular approach

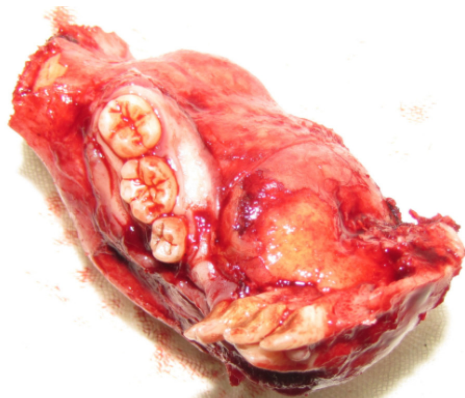


Fig 6: Resected tumor mass

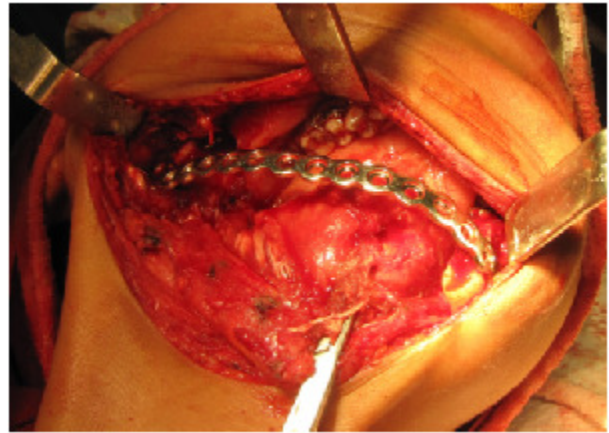


Fig 7: Immediate reconstruction of mandible with reconstruction plate

Postoperative healing was uneventful (Fig. 8). Naso-enteral feeding was continued for 6 days, after which the patient was kept on a liquid oral diet.



Fig 8: Post-operative view of patient

DISCUSSION

Fibromatosis encompasses a group of soft tissue lesions which are characterized histologically by fibroblastic proliferation and clinically by the potential to infiltrate locally and to recur after surgical excision, but not metastasize.

Seper et al.^[11] presented a complete literature of aggressive fibromatosis of the mandible reported between 1960 and 2003. Out of 37 published cases, most (89%) underwent surgical resection with 22% of recurrences reported after an average follow up of 3.8 years. The tumor is very rare in the maxilla. We know only 15 cases that have been reported from 1980 to now^{12, 13}.

The incidence of these lesions in the head and neck is mentioned as from 9.5% to 50% of

all desmoids tumors.[14] Within this area, 40% to 80% of the tumors are located in the neck^[15]. The face is mentioned as the second most frequent site for desmoids lesions, with preponderance in the region of the cheek^[15].

Clinically, AF manifests as a painless, firm, rapidly enlarging mass, fixed to underlying bone or soft tissue. Histologically, AFs are tumors with proliferation of mature fibroblasts with long ovoid nuclei without polymorphism. Abundant collagen is present with the neoplastic cells.

Radiographic findings are variable ranging from periosteal thickening with ill-defined radiolucency to frank bony destruction. CT and MRI show infiltration of soft and hard tissue boundaries^[4].

The osteolysis of the mandible with a large extra oral swelling but without involvement of the mucosal or skin surface could indicate the presence of a primary osseous lesion. Therefore, AF could be misdiagnosed as desmoplastic fibroma, in particular because it has a similar histopathological appearance^[16].

Estrogen, progesterone receptors and anti-estrogen binding site studies may be of clinical importance, as a therapy with hormonal agents might be effective in AF^[17].

According to the literature, surgery is the most common treatment of AF in head and neck with local invasion into the mandible^[18,19]. Extensive and mutilating resection of a benign neoplasm is a difficult decision. However, the disease can result in a lethal outcome. Therefore, complete excision of AF with a generous border of histologically tumor-free tissue is generally recommended^[3,5,20]. When bone is involved, the treatment has to include the affected part of the mandible.

Owing to the locally aggressive progression of AF and patient's uncompleted growth, the treatment of head and neck lesions in young children needs multidisciplinary approach. The therapy alternatives in AF include Chemotherapy^[21] hormonal therapy (antiestrogen), NSAID therapy^[22]. Radiotherapy is reserved for inoperable disease and chemotherapy may be useful as an adjunct.

CONCLUSION

Aggressive fibromatosis presents a diagnostic dilemma and may mimic malignancy. The differential diagnosis with malignant tumors is difficult. Fibromatosis in the maxillofacial region is a very rare among diverse pathologic conditions, and because of the rarity of this tumor, definite treatment regimen is not established, which may be responsible for a high recurrence rate of these tumors. Surgery is the first-line of treatment, however, alternative therapies should be considered, especially in children, to avoid mutilating operations.

REFERENCES

1. Stout AP: Juvenile fibromatoses. *Cancer* 7: 953–978, 1954
2. Zachariades N, Papanicolaou S: Juvenile fibromatosis. *J Craniomaxillofac Surg* 16: 130–135, 1988
3. Hoffman CD, Levant BA, Hall RK: Aggressive infantile fibromatosis: report of a case undergoing spontaneous regression. *J Oral Maxillofac Surgery* 51: 2043–2047, 1993
4. Tullio A, Sesenna E, Raffaini M: Aggressive juvenile fibromatosis. *Minerva Stomatol* 39: 77–81, 1990
5. De Santis D: Fibromatosis of the mandible : case report and review of previous publications. *Br J Oral Maxillofac Surgery* 36: 384–388, 1998
6. Meera Satish Ruparelia 1, Daljit K. Dhariwal : Infantile fibromatosis: a case report and review of the literature. *Br J Oral Maxillofac Surgery* 2011
7. Pack GT, Ehrlich HE. Neoplasms of the anterior abdominal wall with special consideration of desmoid tumours: experience with 391 cases and collective review of the literature. *Int Abstr Surg* 1944;**79**: 177
8. Reitamo JJ, Scheinin TM, Havry P. The desmoid syndrome. New aspects in the cause, pathogenesis and treatment of the desmoids tumor. *Am J Surg* 1986;151:230-7
9. Carr RJ, Zaki GA, Leader MB, Langdon JD. Infantile fibromatosis with involvement of the mandible. *Br J Oral Maxillofac Surg* 1992;30:257-62.
10. Zlotecki RA, Scarborough MT, Morris CG, Berrey BH, Lind DS, Ennekind WF, Markus Jr RB: External beam radiotherapy for primary and adjuvant management of aggressive fibromatosis. *Int J Radiat Oncol Biol Phys* 54: 177–181, 2002
11. Seper L, Burger H, Vormoor J, Joos U, Kleinheinz J: Aggressive fibromatosis involving the mandible—case report and review of the literature. *Oral Surg Oral Med Oral Pathol Oral Radiol Endod* 99: 30–38, 2005
12. Donohue WB, Malexos D, Pham H. Aggressive fibromatosis of the maxilla. Report of a case and review of the literature. *Oral Surg Oral Med Oral Pathol* 1990;**69**:420–6.

13. Tenglong Hua,, Guangping Jing, Kewen Lv : Aggressive fibromatosis in the maxilla. *Br J Oral Maxillofac Surgery* 2009
14. Das Gupta TIC, Brasfield RD, O'Hara J. Extra-abdominal desmoids: a clinicopathological study. *Ann Surg* 1969; 170:109-21.
15. Conley T, Healey WV, Stout AD. Fibromatosis of the head and neck. *Am J Surg* 1966;112:609-14.
16. Addante RR, Laskin JL. Large right mandibular mass. *J Oral Maxillofac Surg* 1985;43:531-6.
17. Wilcken N, Tattersall MHN. Endocrine therapy for desmoids tumors. *Cancer* 1991;68:1384-8.
18. Melrose RJ, Abrams AM. Juvenile fibromatosis affecting the jaws. Report of 3 cases. *Oral Surg Oral Med Oral Pathol Oral Radiol Endod* 1980;49:317-24
19. Akama MK, Chindia ML, Guthua SW, Nyong'o A. Extraabdominal fibromatosis invading the mandible: case report. *East Afr Med J* 2002;79:49-51
20. Spear MA, Jennings LC, Mankin HJ, Spiro IJ, Springfield DS, Gebhardt MC, et al. Individualizing management of aggressive fibromatoses. *Int J Radiat Oncol Biol Phys* 1998;40:637-45.
21. Azzarelli A, Gronchi A, Bertulli R, Tesoro JD, Baratti D, Pennacchioli E, et al. Low-dose chemotherapy with methotrexate and vinblastine for patients with advanced aggressive fibromatosis. *Cancer* 2001;92:1259-64.
22. Lackner H, Urban C, Kerbl R, Schwinger W, Beham A. Noncytotoxic drug therapy in children with unresectable desmoids tumors. *Cancer* 1997;80:334-40.